

Tikrit University

College of Nursing

Basic Nursing Sciences



First Year - 2023-2024

Anatomy

accessory organs OF GIT:

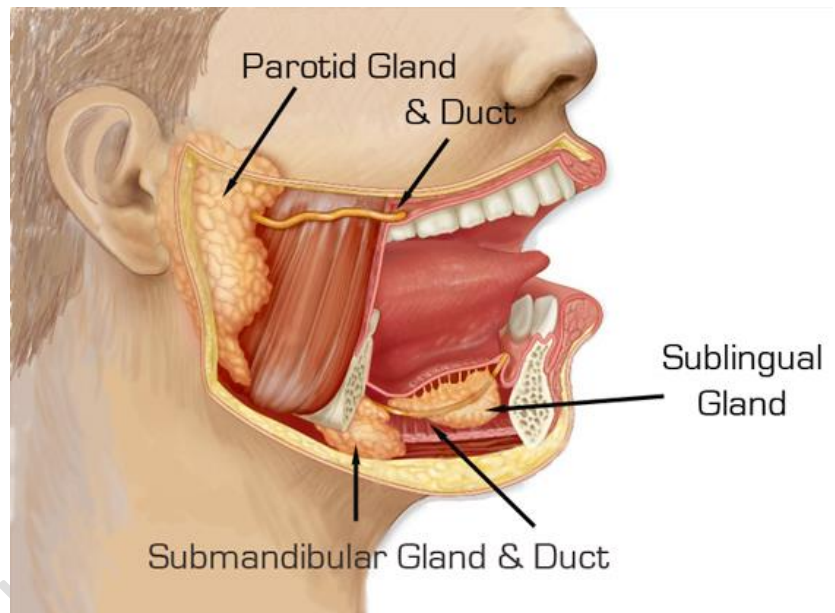
Prof.Dr. Abdul-Jabbar Al-Samarrae

▪ **The accessory organs OF GIT:**

❖ **the Salivary glands**

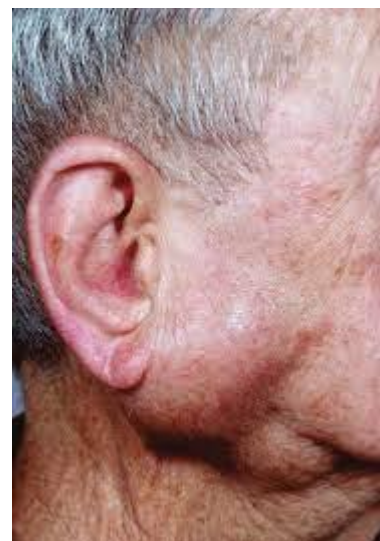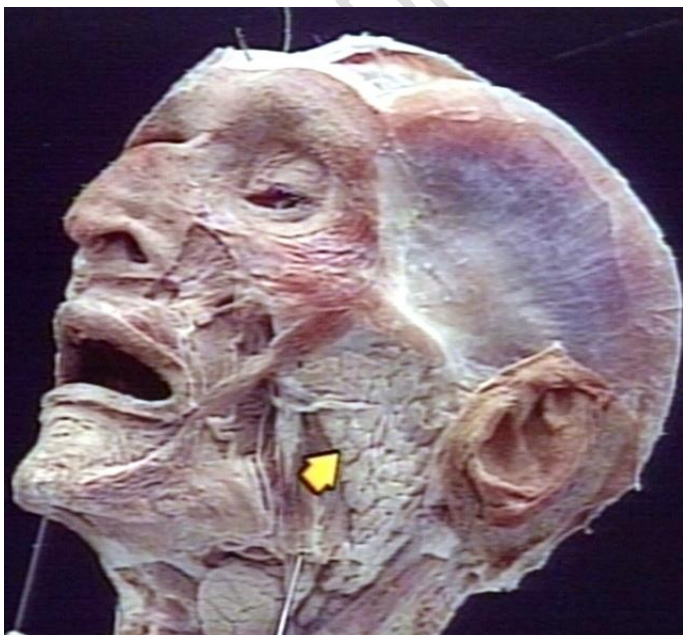- 1- Parotid
- 2- Submandibular
- 3- Sublingual

❖ They open by ducts into oral cavity



1- Parotid

- Located just in front of and below each ear.

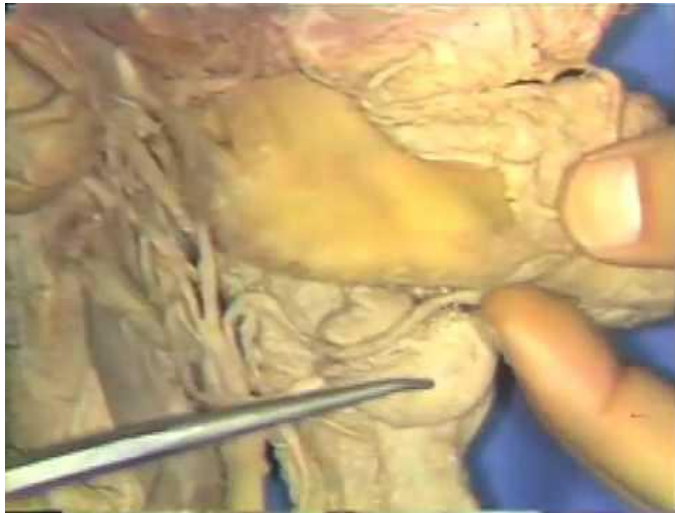

Normal

inflamed

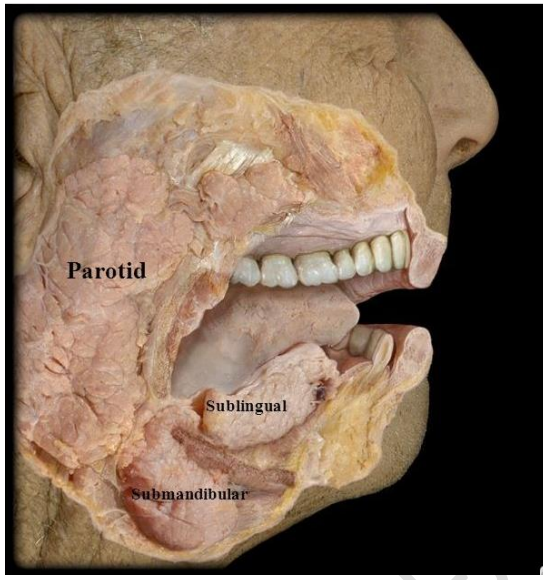
2- submandibular

- located **under the lower jaw**



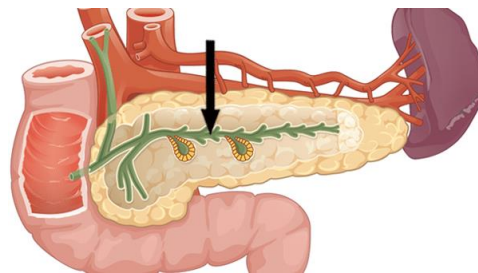
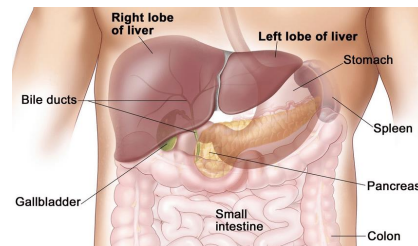
3- sublingual

- located **under the tongue**



❖ pancreas

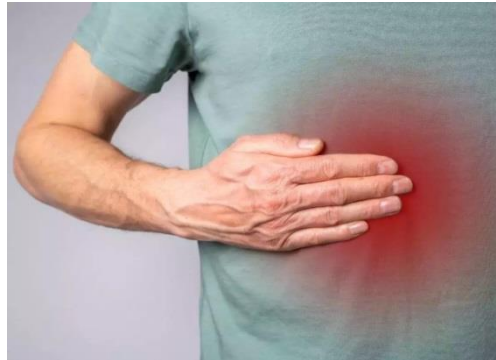- ☒ is located behind the stomach in the **upper left abdomen**
- ☒ Has exocrine part produce enzymes
- ☒ Its duct opens into the **duodenum**



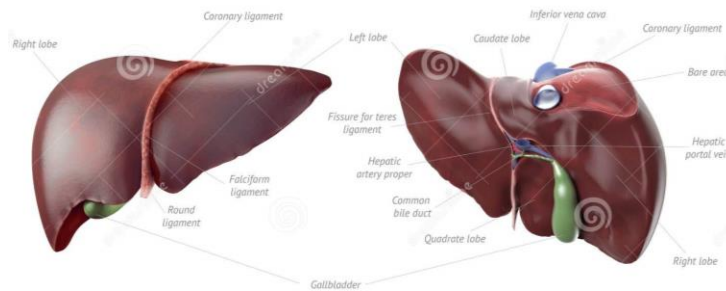
❖ Liver and gallbladder

❖ Liver:

- It lies under the diaphragm
- It occupies mainly in right hypochondrium
- Weight: average 1500 g.
- make and secrete bile



- liver has four lobes:
 1. right lobe
 2. left lobe
 3. Caudate lobe
 4. Quadrate lobe



❖ Gallbladder

Location

- Location In the gallbladder fossa of the liver.
- Pear-shaped organ
- stores and releases bile in duodenum

